

## Patient with previously misdiagnosed total situs inversus

**Tomasz Senderek** <sup>A-F</sup> 

Andrzej Frycz Modrzewski Krakow University

A – Research concept and design, B – Collection and/or assembly of data, C – Data analysis and interpretation, D – Writing the article, E – Critical revision of the article, F – Final approval of the article

### *Abstract*

**Background:** The case of 30 years-old patient with recently diagnosed dextrocardia is discussed herein.

**Material and methods:** Dextrocardia, a specific anomaly of heart position in the chest, usually associated with situs inversus and sometimes by Kartener's syndrome was diagnosed in the patient by careful physical examination proven by electrocardiography and imaging.

**Results:** Specific ECG changes were crucial to recognize the syndrome. The patient presented total situs inversus in physical examination. The case is a good exemplification of frequent dextrocardia oversight, since it has not been found during previous 30 years by medical professionals, including both pediatrician and occupational medicine specialist.

**Conclusions:** The attention should be always turned to make a proper diagnosis because it allows to recognize properly additional diseases as well as avoid misdiagnosis in future.

**Keywords:** ECG, dextrocardia, total situs inversus

### *Introduction*

Dextrocardia with situs inversus is a congenital syndrome in which the organs are mirrored or reversed. It can be correlated with Kartagener's syndrome (sinusitis and bronchiectases). It was first described in the first half of the 17<sup>th</sup> century by Hieronymus Fabricius and Marco Aurelio Severino [1].

If dextrocardia is associated with isomerism, polysplenia syndrome is likely to be diagnosed. Most patients with situs inversus are asymptomatic [2]. When these patients develop new symptoms or conditions, such as coronary artery disease or hypertension, they are treated like the general population, but diagnosing them can be more difficult [3,4].

### *Case description*

A 30-year-old patient with an unknown history of dextrocardia came in (he was admitted to the out-patient cardiology unit) to have his blood pressure

✉ Corresponding author: Tomasz Senderek; e-mail: tomesenderek@gmail.com

The patient had had an ECG performed on two previous occasions for occupational medicine, and both times there was a problem with the ECG machine and it had to be redone on another machine.

BT1-08 LC 11012018 092508 5340000R100 d3245

pacjent

im: ruzewski  
pocel  
data urodzenia:

BT1-08 LC 11012018 092508 5340000R100 d3245

urazgi lekarza

automat 25 mm/s 10/10 mm/mV synchro HR = 87  
100% 0% 1% 2% 3% 4% 5% 6% 7% 8% 9% 10%

BT1-08 LC 11012018 092508 5340000R100 d3245

BT1-08 LC 08LC-0733411

At the cardiologist's office an ECG with right-sided precordial leads (Figure 2 and 2a) was performed. The right-sided precordial lead ECG showed normalized R wave progression. These summations of ECG findings are suggestive of dextrocardia. In addition to this, an apical impulse was palpated in the right 5<sup>th</sup> intercostals space, 1.75 cm lateral to the right midclavicular line. The lower liver span was palpated in the left upper quadrant of the abdominal cavity.

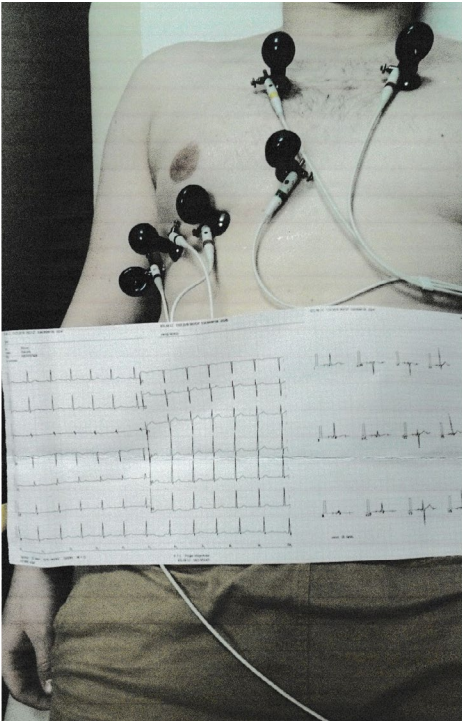
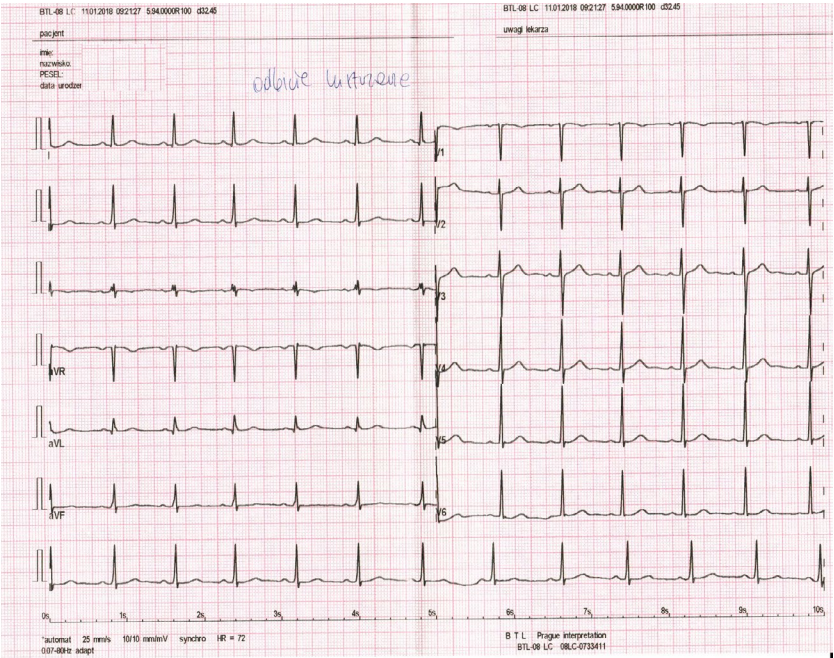


Fig. 2, 2a. ECG with right-sided precordial leads

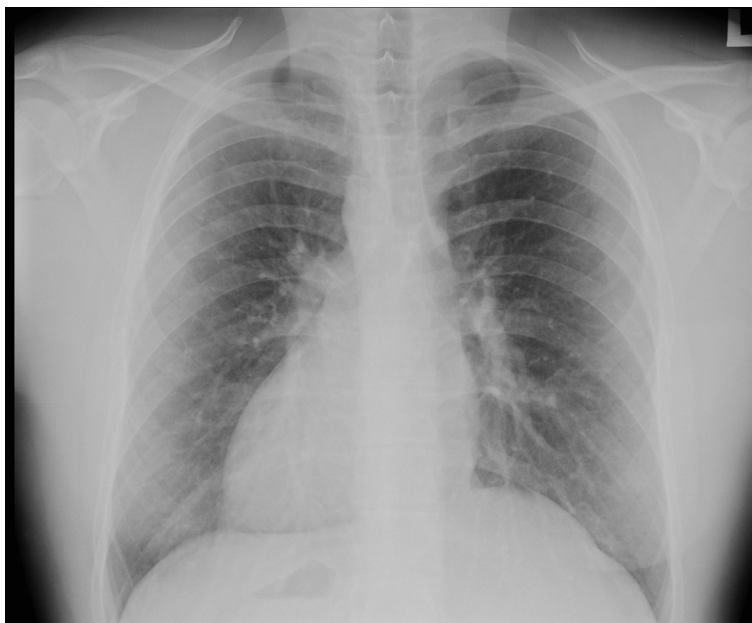

Fig. 3. Chest radiography

**IMAGES:** A 12-lead surface electrocardiography (ECG) with both standard precordial leads (Figure 1) and right-sided precordial leads (Figure 2) was performed. The standard ECG was notable for inverted P waves in the lateral leads (I and aVL), suggesting rightward atrial electric forces and no R wave progression. The right-sided precordial lead ECG showed normalized R wave progression. These summations of ECG findings are suggestive of dextrocardia. There were also T wave inversions in I and aVL, which are also consistent with dextrocardia but less specific than the other findings. The patient subsequently underwent echocardiography, which confirmed dextrocardia with proper anatomy and function.

### ***Results***

Because of possible anomalies [5], the patient subsequently underwent an echocardiography which confirmed dextrocardia with proper anatomy and function. The patient also underwent an ultrasound examination of the abdomen to check for possible anomalies. All organs were normal but located on the opposite side. The patient was prescribed ACEI to control his blood pressure. After a few days of treatment the blood pressure was normalized.

**Summary:** For the diagnosis of dextrocardia a proper physical examination supported by a properly interpreted ECG is crucial [6,7]. An appropriate diagnosis can help avoid misleading symptoms of typical diseases.



## Conclusions

We confirmed the presence of dextrocardia with situs inversus using chest radiography (Fig. 3) and abdomen ultrasound.

## References

1. Cleveland M. Situs inversus viscerum: anatomy study. *Arch Surg.* 1926; 13:343, <https://doi.org/10.1001/archsurg.1926.01130090042003>.
2. Bohun CM, Potts JE, Casey BM, Sandor GG. A population-based study of cardiac malformations and outcomes associated with dextrocardia. *Am J Cardiol.* 2007 Jul 15;100(2):305–309. Epub 2007 May 25.
3. Hudzik B, Polonski L. Incidentally found situs inversus with dextrocardia: inferior myocardial infarction in an 86-year-old woman. *Ann Noninvasive Electrocardiol.* 2012 Oct;17(4):398–400, <https://doi.org/10.1111/j.1542-474X.2012.00513.x>. Epub 2012 Aug 13.
4. al-Khadra AS. Images in cardiovascular medicine. Mirror-image dextrocardia with situs inversus. *Circulation.* 1995 Mar 1;91(5):1602–1603.
5. Pierre D. Maldjian and Muhamed Saric. Approach to Dextrocardia in Adults: Review *American Journal of Roentgenology.* 2007;188:S39–S49, <https://doi.org/10.2214/AJR.06.1179>.
6. Ogunlade O, Ayoka AO, Akomolafe RO, Akinsomisoye OS, Irinoye AI, Ajao A, Asafa MA. The role of electrocardiogram in the diagnosis of dextrocardia with mirror image atrial arrangement and ventricular position in a young adult Nigerian in Ile-Ife: a case report. *J Med Case Rep.* 2015;9:222.
7. He J, Sun Y, Zhang X, Wang Y, Zhong J, Lin F, Liu Y. Emergent percutaneous coronary intervention for acute myocardial infarction in patients with mirror dextrocardia: case reports and brief review. *Cardiovasc Diagn Ther.* 2016 Jun;6(3):267–273, <https://doi.org/10.21037/cdt.2015.12.12>.